

Cite this article as: Neural Regen Res. 2011;6(6):418-422.

NeuroAid (MLC601) versus piracetam in the recovery of post-infarct homonymous hemianopsia^{☆●}

Kavian Ghandehari¹, Zahra Izadi Mood², Saeed Ebrahimzadeh³, David Picard⁴, Yue Zhang⁵

¹Neuroscience Research Center, Mashhad University of Medical Sciences, Mashhad, Iran, P.O. Box 91766-99199
²Department of Traditional Medicine, Mashhad University of Medical Sciences, Mashhad, Iran, P.O. Box 91766-99199
³Department of Biostatistics, Mashhad University of Medical Sciences, Mashhad, Iran, P.O. Box 91766-99199
⁴National Neuroscience Institute, Singapore; Moleac Ltd, Helios 09-08, 11Biopolis Way, Singapore 138667
⁵National Neuroscience Institute, Singapore; Moleac, Ltd, Helios 09-08, 11Biopolis Way, Singapore 138667

Abstract

In the clinic, the natural recovery rate of homonymous hemianopsia caused by occipital lobe infarction is low. At present, ideal therapeutic effects of piracetam for improving visual field defects following homonymous hemianopsia do not exist. The present randomized, controlled study compared the effects of NeuroAid (MLC601) versus piracetam for improving visual field defects in post-infarct homonymous hemianopsia patients matched for age and sex. After 3 months of treatment with NeuroAid (MLC601) or piracetam, visual field defects were significantly improved, compared with prior to treatment ($P < 0.001$). After treatment with MLC601, relative reduction of right and left visual field defects was 45% and 45.7%, respectively, while relative reduction after treatment with piracetam was 32.7% and 30.3%, respectively. These findings suggested that MLC601 was superior to piracetam for reducing visual field defects in homonymous hemianopsia patients.

Key Words: MLC601; piracetam; post-infarct recovery; stroke

Kavian Ghandehari[☆], M.D.,
FLSP, RCPC, Professor of
Cerebrovascular Disease,
Neuroscience Research
Center, Mashhad University
of Medical Sciences, Mash-
had, Iran, P.O. Box
91766-99199

Corresponding author: Ka-
vian Ghandehari, Depart-
ment of Neurology, Ghaem
Hospital, Ahmadabad Street,
Mashhad, Iran, P.O.Box
91766-99199 kaviang-
handehari@yahoo.com,
Ghandeharik@mums.ac.ir

Received: 2010-11-02
Accepted: 2011-01-27
(NY20101123004/H)

Ghandehari K, Izadi Mood Z,
Ebrahimzadeh S, Picard D,
Zhang Y. NeuroAid
(MLC601) versus piracetam
in the recovery of post-infarct
homonymous hemianopsia.
Neural Regen Res.
2011;6(6):418-422.

www.crter.cn
www.nrronline.org

doi:10.3969/j.issn.1673-5374.
2011.06.003

INTRODUCTION

Recovery remains incomplete in many stroke patients, in particular damage to visual symptoms as a result of occipital lobe infarction. Low recovery of visual symptoms, secondary to visual cortex lesions, is due to low neuroplasticity in this brain region^[1]. Homonymous hemianopsia (HH) typically results from posterior cerebral artery infarctions, and the condition leads to severe disabilities in routine living and working activities, e.g., driving a car or computer-based jobs^[2].

Research success and clinical recovery of HH in stroke patients has been limited and disappointing^[2]. Spontaneous recovery remains low, and visual rehabilitation intervention is not available^[2]. NeuroAid (MLC601, Moleac Pte., Singapore) is a traditional Chinese medicine, which combines nine herbal components and five animal components, and is available and registered by Iranian drug authorities as a neuroprotective drug. The therapeutic effects of MLC601 on stroke recovery could be related to its role in neuronal protection and plasticity, as well as growth of new neuronal pathways^[3]. Piracetam is a syn-

thetic neuroprotective agent that has been routinely used as a post-stroke drug in Iran for the past 2 decades. The present study compared the effects of MLC601 with piracetam in Iranian ischemic stroke patients presenting with visual field defects.

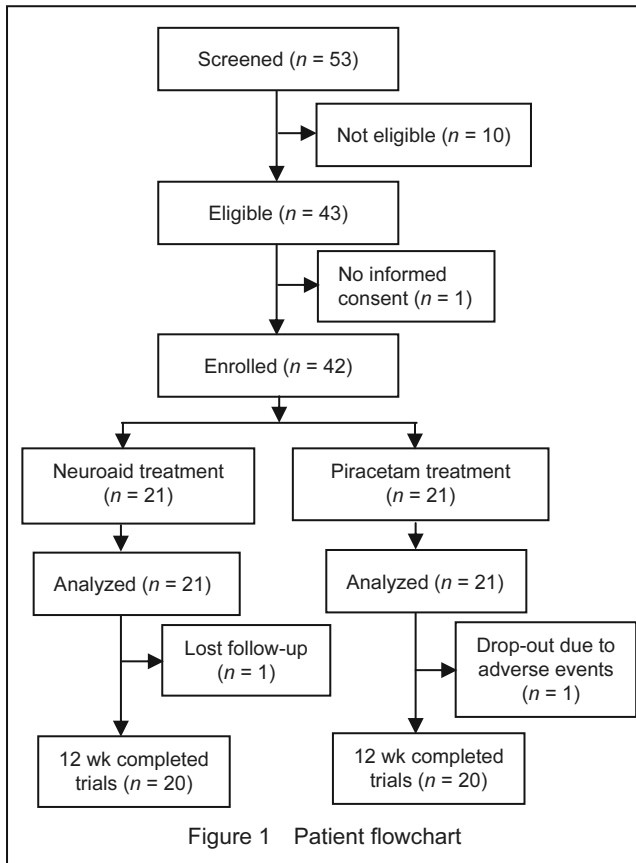
RESULTS

Quantitative analysis of subjects

A total of 53 consecutive stroke patients with posterior cerebral artery territory infarction were screened and initially included in the study. In total, 40 cases were included in the final analysis. The flowchart for this clinical trial is shown in Figure 1. Patients were randomly assigned to MLC601 and piracetam groups (20 patients per group) and received a 3-month course of either MLC601 or piracetam, respectively. A total of 11 patients from the MLC601 group and 10 patients from the piracetam group exhibited right-sided HH.

Baseline data

MLC601 and piracetam groups consisted of 20 patients each (10 females and 10 males). Mean ages were 62 ± 12.9 years and 59.2 ± 14.4 years in the MLC601 and piracetam groups, respectively.



Visual field defects

Visual field defects of MLC601 and piracetam groups at baseline and at 3-month follow-ups are shown in Table 1.

Table 1 Visual field defects at baseline and at 3-month follow-up in MLC601 and piracetam groups ($\bar{x}\pm s$)

Group	Right visual field defects (mm ²)			
	Baseline	3 mon	Recovery	P
MLC601	1 270.6±200.9	699.1±407.6	571.6±465.1 -45%	< 0.001
Piracetam	1 295.1±167.2	871.7±354.3	423.5±373.1 -32.7%	< 0.001
P value	0.678	0.161		

Group	Left visual field defects (mm ²)			
	Baseline	3 mon	Recovery	P
MLC601	1 325.4±132.2	720.3±408.7	605.2±448.1 -45.7%	< 0.001
Piracetam	1 324.0±120.1	923.4±296.6	400.6±332.8 -30.3%	< 0.001
P value	0.972	0.080		

There were significant differences in the amount of visual field defects between baseline and at 3-month follow-ups in the right and left visual fields in each group [(MLC601 right: $t = 5.49$, $df = 19$, $P < 0.001$; piracetam right: $t = 5.08$, $df = 19$, $P < 0.001$) and (MLC601 left: $t = 6.04$, $df = 19$, $P < 0.001$; piracetam left: $t = 5.38$, $df = 19$, $P < 0.001$) respectively]. There was no significant difference in

mean right and left visual field defects between the two treatment groups at baseline and 3-month follow-ups [(baseline, right: $t = -0.418$, $df = 38$, $P = 0.678$; left: $t = 0.035$, $df = 38$, $P = 0.972$) and (3-month follow-up, right: $t = -1.429$, $df = 38$, $P = 0.161$; left: $t = -1.799$, $df = 38$, $P = 0.080$), respectively]. Following treatment with MLC601 for 3 months, relative reduction of right and left visual field defects was 45% and 45.7%, respectively. However, following treatment with piracetam for 3 months, the relative reduction was 32.7% and 30.3%, respectively. There was no significant difference in the influence of age on recovery of right (MLC601 group, $df = 2$, $P = 0.768$; piracetam group, $df = 2$, $P = 0.354$) or left visual field defects (MLC601 group, $df = 2$, $P = 0.621$; piracetam group, $df = 2$, $P = 0.413$) in each group. In addition, there was no significant difference in the influence of gender on recovery of right ($t = 0.983$, $df = 18$, $P = 0.339$) or left visual field defects ($t = 0.769$, $df = 18$, $P = 0.452$) in the MLC601 group. However, the influence of gender on recovery of right visual field defects was not significant in the piracetam group ($t = 1.339$, $df = 18$, $P = 0.197$), but was significant in the left side ($t = 2.287$, $df = 18$, $P = 0.037$). The percentage of HH recovery was classified into 4 categories: $\leq 25\%$, 26–50%, 51–75%, and $> 75\%$. Distribution of HH recovery was not significantly different between MLC601 and piracetam groups ($X^2 = 0.376$, $df = 3$, $P = 0.329$). In addition, the influence of age ($X^2 = 1.86$, $df = 3$, $P = 0.154$) and gender ($X^2 = 5.879$, $df = 3$, $P = 0.091$) on distribution of HH recovery was not significant in all of the 40 cases. In the MLC601 group, the influence of gender on distribution of HH recovery was not significant in right ($X^2 = 5.033$, $df = 3$, $P = 0.204$) or left ($X^2 = 4.667$, $df = 3$, $P = 0.350$) visual fields. In addition, in the piracetam group, the influence of gender on distribution of HH recovery was not significant in right ($X^2 = 4.203$, $df = 3$, $P = 0.145$) or left ($X^2 = 3.816$, $df = 2$, $P = 0.069$) visual fields.

Adverse events

Side effects, including abdominal discomfort, were observed in 10% (2/20) of MLC601 group patients. However, no patients were excluded, because side effects were mild in the MLC 601 group. Side effects, which included headache, drowsiness, and dizziness, were observed in 10% (2/20) of piracetam group patients. One patient treated with piracetam was excluded from the piracetam group due to severe headaches. Despite the use of appropriate anti-platelet and anti-coagulation therapies in two therapeutic arms, hemorrhagic complications were not observed in patients from the MLC601 or piracetam groups.

DISCUSSION

The pharmacological industry has identified a large number of compounds that can be utilized for clinical testing of the pathophysiological cascades associated with vessel occlusions and irreversible cell death. Piracetam is one of the major agents considered to exhibit

neuroprotective effects in humans^[4]. The Piracetam Acute Stroke Study (PASS), which began in 1989 and was published in 1997, was a double-blinded, randomized, controlled trial during the acute treatment of ischemic stroke^[5]. A greater number of patients completely recovered in the piracetam group (18.8%) than in the placebo group (13.6%). In addition, the level of function requiring constant care was more frequent in the placebo group (25%) than in the piracetam group (19.6%)^[5]. Impairment and disability were not significantly different between placebo and piracetam patients, but there was significantly less residual aphasia after 3 months of treatment^[5]. Oral forms of piracetam (800 mg film-coated tablets and 200 mL of 20% solution, 1 mL = 200 mg piracetam) have been widely used as routine neurotropic drugs for stroke recovery in Iran over the past 2 decades. However, available data does not support the routine use of piracetam for managing patients with acute ischemic stroke, and piracetam trials do not provide definite evidence for mortality in acute ischemic stroke^[5-7]. Piracetam improves microcirculation and delivery of oxygen to ischemic tissues, as well as appropriate ionic environments surrounding ischemic neurons^[7]. MLC601 plays a role in neuronal protection and plasticity by establishing new neuronal pathways and synaptogenesis. MLC601 is thought to enhance recovery of stroke patients, even at months post-stroke^[8]. The mechanisms of action of MLC601 were recently analyzed *in vitro* and *in vivo*^[3, 8]. A previous study showed that MLC601 influences neurogenesis and development of axonal and dendritic connections^[3]. Brain recovery can consist of the reconstruction of neuronal pathways, and MLC601 assists in this process, particularly in posterior cerebral infarct^[9]. Because MLC601 is typically administered to a higher socioeconomic group of Iranian stroke patients, who usually receive better rehabilitation therapy, the present study focused only on isolated HH in stroke patients, who do not receive rehabilitation and speech therapy. This research strategy eliminated the therapeutic bias of comparing the neurotropic effects of MLC601 and piracetam. Because of ethical limitations, it was not possible to compare the therapeutic effects of MLC601 with placebo in Iran, because piracetam has been routinely and traditionally used as a neurotropic drug in Iranian ischemic stroke patients for the past 2 decades. Previous clinical studies performed in China demonstrated that MLC601 enhances neurological recovery in stroke patients and improves functional outcomes^[3, 9]. A current large-scale, randomized, controlled trial in South East Asia is evaluating the impact of 3 months of treatment with MLC601 on patients through the use of neurological disability scores^[8]. An additional double-blinded, placebo-controlled, randomized, phase II pilot study in Singapore investigated the potential efficacy of MLC601 in enhanced recovery after stroke^[3]. There was no significant difference in MLC601 effects on motor recovery following treatment within a month of stroke onset^[3]. However, subgroup analysis in this study showed that

the MLC601 group performed better than the placebo group when severity of stroke was great. In addition, there was a very strong tendency towards better recovery in posterior circulation infarction^[3]. Nevertheless, it was difficult to draw conclusions, due to the small number of patients involved ($n = 7$) and imbalanced baseline scores^[3]. Our pilot comparative study showed a non-significant difference in MLC601 *versus* piracetam therapeutic effects on HH recovery in patients with posterior cerebral artery territory infarction. The relative reduction in right and left visual field defects following treatment with MLC601 was 45% and 45.7%, respectively. However, following piracetam treatment, it was 32.7% and 30.3%, respectively. Results demonstrated a 50% greater therapeutic effect in improved visual fields with MLC601 than with piracetam, although the absence of a control group did not allow for a differentiation between therapeutic recovery and spontaneous recovery of HH. Nevertheless, due to the absence of visual rehabilitation interventions, and assuming similar spontaneous recovery between the groups, the recovery differences in MLC601 and piracetam groups could reveal a therapeutic influence of these neurotropic agents. Hemostasis, hematological, and biochemical safety of MLC601 has been established in three clinical trials^[3, 9-10]. In addition, results from the present comparative study revealed a good safety profile for MLC601 and piracetam. In conclusion, MLC601 promoted better recovery of post-stroke HH, compared with piracetam. MLC601 treatment in patients with posterior cerebral artery infarction and HH was proven beneficial.

SUBJECTS AND METHODS

Design

A prospective, observational study.

Time and setting

The present study was conducted at Ghaem Hospital, Mashhad, Iran during 2009–2010.

Subjects

A total of 40 stroke patients with posterior cerebral artery territory infarction, aged 60.0 ± 13.6 years, who received treatment in Ghaem Hospital (Mashhad, Iran), were included in this study.

Patients were eligible for inclusion in the comparative study if all of the following criteria were fulfilled at baseline^[3, 8, 10]:

- 1- Aged 18 years old or greater;
- 2- Time window of < 1 week after onset of ischemic symptoms;
- 3- Clinical presentation of ischemic symptoms, which were diagnosed as pure HH without neglect, and macular sparing, as confirmed by routine perimetry;
- 4- Posterior cerebral artery territory infarction with isolated occipital lobe involvement, as confirmed by brain CT or MRI;
- 5- Females were eligible to participate in the study if they were of non-child-bearing potential; *e.g.*,

post-menopausal period, hysterectomy, or use of oral contraceptive pills;

6- Patient, or his/her legally acceptable relative, provided signed informed consent.

A subject was not eligible for inclusion in the study if he or she corresponded to any of the following criteria at baseline^[3-6]:

- 1- Underwent recent thrombolysis;
- 2- Evidence of intracerebral hemorrhage upon brain CT or MRI;
- 3- Rapidly improved neurological deficits;
- 4- Stupor or coma, as defined by a score of < 5 on the Glasgow Coma Scale, which makes it impossible to perform perimetry;
- 5- Other significant non-ischemic brain lesions that could affect functional disability; e.g., intracranial tumor or demyelinating lesions;
- 6- Coexistence of ophthalmologic disease that could affect HH evaluation, e.g., cataract, optic neuritis, or retinal abnormalities;
- 7- Co-existing systemic diseases; e.g., terminal cancer, renal failure, liver failure, or psychosis;
- 8- Patients with lacunar infarction in the posterior cerebral artery territory;
- 9- Aphasia or any other cognitive disabilities that prevented cooperation with study instructors;
- 10- History of craniotomy or epilepsy seizure;
- 11- History of previous stroke, which presented with visual field defects;
- 12- Recurrence of stroke during 3-month follow-up period, which presented with visual field defects;
- 13- Patients required rehabilitation or speech therapy.

Methods

Drug treatment

All included patients underwent brain CT or MRI examinations, laboratory examinations (complete blood count, blood urea, serum creatinine, blood glucose, liver enzymes, serum bilirubin, serum electrolytes, urine albumin, and glucose), and electrocardiogram examination. All patients received standard stroke care, including appropriate anti-platelet therapy or anti-coagulation therapy (aspirin with or without dipyridamole, clopidogrel, warfarin), as well as control of vascular risk factors. Either MLC601 or piracetam was administered as an add-on to other medications based on patient condition^[5, 9]. MLC601 was manufactured by Shitian Pharmaceuticals in China and was licensed by Iranian drug authorities as a neuroprotective drug. MLC601 consisted of nine herbal components^[3] (*Radix astragali*, *Radix Salviae Miltiorrhiae*, *Radix paeoniae rubra*, *Rhizoma chuanxiong*, *Radix angelicae sinensis*, *Carthamus tinctorius*, *Prunus persica*, *Radix polygalae*, and *Rhizoma Acori Tatarinowii*^[8]) and five animal components^[3] (*Hirudo*, *Eupolyphaga seu Steleophaga*, *Calculus bovis artifactus*, *Buthus martensii*, and *Cornu Saigae Tataricae*^[6]). Each patient from the MLC601 group was administered MLC 601, 4 capsules (400 mg/capsule) once, 3 times a day for 3 months. Piracetam is a neurotropic drug initially produced by UCB

S.A in Belgium, but it is now produced in Iran by Daru Pakhsh Pharmaceutical Company, Tehran. Each piracetam film-coated tablet (800 mg) contained colloidal anhydrous silica, magnesium stearate, Macrogol 6000, croscarmellose sodium, hydroxypropylmethylcellulose, Macrogol 400, and titanium dioxide^[6]. Stroke patients in the piracetam group were administered piracetam, 2 tablets once, 3 times a day for 3 months^[6].

Evaluation of visual fields

Stroke patients in each therapeutic group underwent standard perimetry at baseline, as well as a follow-up perimetry 3 months later. Outline of the visual field defect was carefully determined in the perimetry sheet by using a point grid. Subsequently, the surface area of each visual field defect was manually calculated, based on square millimeter. All perimetries were performed by a single ophthalmologist, who was blinded to the drug group. The degree of recovery of visual fields was determined by comparing baseline and 3-month perimetries according to the above-described method.

Statistical analysis

Calculation of mean and standard deviation for surface of visual field defects revealed necessity of at least 16 cases from each therapeutic group, resulting in a significance level of 5% and 99% power (Based on a drop-off rate of 20% and a 1: 1 ratio, 20 patients were required for each trail arm). Distribution of variables was normal and based on One-Sample Kolmogorov-Smirnov test for the entire population of 40 patients, as well as in each therapeutic group separately ($P > 0.05$). Independent and paired *t*-tests and chi-square tests were used for statistical analysis.

Author contributions: Kavian Ghandehari designed and performed the research and wrote the paper. Zahra Izadi Mood performed the research. Saeed Ebrahimzadeh analyzed related data. David Picard and Yue Zhang wrote the paper.

Conflicts of interest: None declared.

Ethical approval: The present study received approval from the Ethics Committee of Ghaem Hospital (Mashhad, Iran).

REFERENCES

- [1] Buxbaum LJ, Ferraro MK, Veramonti T, et al. Hemispatial neglect: Subtypes, neuroanatomy, and disability. *Neurology*. 2004;62(5): 749-756.
- [2] Biller J, Love BB. Ischemic cerebrovascular disease. In: Bradely NG, Daroff RB, Fenichel GM, Jankovic J, eds. *Neurology in Clinical Practice*. 5th ed. Philadelphia: Butterworth-Heinemann. 2008:1245.
- [3] Kong KH, Wee SK, Ng CY, et al. A double-blind, placebo-controlled, randomized phase II pilot study to investigate the potential efficacy of the traditional Chinese medicine Neuroaid (MLC 601) in enhancing recovery after stroke (TIERS). *Cerebrovasc Dis*. 2009;28:514-521.
- [4] Warlow CP, Van Gijn J, Dennis M, et al. *Stroke: Practical Management*. 3rd ed. London: Blackwell Publishing. 2008:599.
- [5] De Den PP, De Reuk J, Deberdt W, et al. Treatment of acute ischemic stroke with Piracetam. *Stroke*. 1997;28:2347-2352.
- [6] Ricc S, Celami MG, Cantisani TA, et al. Piracetam in acute stroke: a systematic review. *J Neurol*. 2000;247:263-266.

- [7] Hankey GJ, Ricci S, Celani MG, et al. Piracetam for acute ischemic stroke. *Stroke*. 2006;37:2191-2192.
- [8] Venketasubramanian N, Chen CL, Gan RN, et al. A double-blind, placebo-controlled, randomized, multicenter study to investigate Chinese medicine Neuroaid efficacy on stroke recovery (CHIMES study). *Int J Stroke*. 2009;4:54-60.
- [9] Siow CH. Neuroaid in stroke recovery. *Eur Neurol*. 2008;60:264-266.
- [10] Chen C, Venketasubramanian N, Gan RN, et al. Dangi Piantag Jiaonang (DJ), a traditional Chinese medicine, in poststroke recovery. *Stroke*. 2009;40:859-863.
(Edited by Abrams GMKim WK, Villa RF/Song LP)